

PATIENT

Tux Opalinski

SPECIES

Canine

BREED

Border Collie

SEX

MN

AGE

13yr

WEIGHT

61lb

INTERPRETED BY

Eric Lindquist, DMV
DABVP, Cert. IVUSS

IMAGING PERFORMED BY

Dr Jenni Tudini, DVM

HOSPITAL NAME

Fetch the Vet Mobile
Veterinary Practice

REFERRING VET

Dr Holly Guenther

INVOICE

24174

DATE

03/11/2026

PRESENTING CLINICAL SIGNS

- Patient previously had both echo and abdominal scan 12 months ago (through Sonopath) and this is a routine follow up scan. Patient was diagnosed with Stage B2 valvular disease at that time and he has been receiving Vetmedin 5mg (1 1/2 tabs BID) since. He was found to have a low grade arrhythmia during that scan that hasn't displayed clinically. He was also found to have a nodule consistent with splenic hyperplasia. Patients health appears stable and owner is wanting a re-evaluation but not because of clinical change

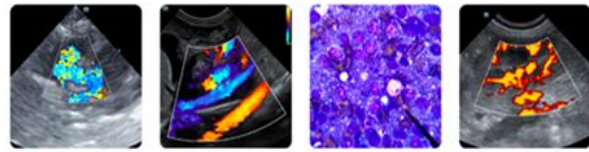
Abnormal PE/Chem/CBC/UA Results: Exam: - Oral exam - mild to moderate tartar present - H/L - grade 3/6 murmur, difficult to hear over his panting/shaking but there seems to be an intermittent arrhythmia - M/S - patient does have some hind limb weakness - CBC - WNL but HCT slowly dropping and is low normal - Chem - SDMA 15, creat 1.8, BUN 43, ALT 131, AST 63, ALP 568 - T4 - WNL

ULTRASONOGRAPHIC EXAMINATION OF THE ABDOMEN AND HEART

CANINE CARDIAC PARAMETERS	MR VMAX (m/s)	TR VMAX (m/s)	LA/AO M-mode	LA/AO (Heart Base; Swe)	FS (%)	EF (%)	EPSS (cm)
NORMAL PARAMETER	4.5-5.5	<2.7	1.3	Up to 1.6	28-40	40-100	<0.6
PATIENT	>5.0	--	--	1.1	58	89	0.1
CANINE CARDIAC PARAMETERS	HR (BPM)	AV VMAX (m/s)	PV MAX (m/s)	BODY WEIGHT	LAD LA MAX 4 Chamber	LVIDd Avg; 2D and m-mode short axis (cm)	LVIDs Avg; 2D and m-mode short axis (cm)
NORMAL PARAMETER	50-100	0.7-1.7	0.7-1.6				
PATIENT	--	--	100	61lb	4.0	3.27	--

Cardiac Presentation

The echocardiogram in this patient demonstrated normal left atrial size based on 3 different LA measurement methods. Chamber volumes and echogenicity were normal. The cranial and caudal mitral valve leaflets presented vegetative thickening consistent with endocardiosis. Doppler indicated measurable insufficiency. The left ventricle presented thicknesses with linear contour and was not dilated nor restricted. The myocardium presented normal echogenicity without subjective evidence of significant fibrotic or ischemic disease. Contractility of the ventricular walls was adequate and in normal range for this patient evidenced by the fractional shortening measurement and subjective evaluation of the different regions of the myocardium. The left ventricular outflow tract demonstrated normal laminar flow and subjective structural integrity. The right atrium and auricle revealed normal size, structure and content. No evidence of masses was noted or chamber overload. Tricuspid valvular assessment demonstrated adequate linear morphology. The right ventricle was of normal size (1/3



PATIENT

Tux Opalinski

SPECIES

Canine

BREED

Border Collie

SEX

MN

AGE

13yr

WEIGHT

61lb

INTERPRETED BY

Eric Lindquist, DMV
DABVP, Cert. IVUSS

IMAGING PERFORMED BY

Dr Jenni Tudini, DVM

HOSPITAL NAME

Fetch the Vet Mobile
Veterinary Practice

REFERRING VET

Dr Holly Guenther

INVOICE

24174

DATE

03/11/2026

diameter of LV), chordae structure, myocardial echogenicity and thickness. Pulmonic tract assessment revealed normal valve structure, laminar flow, and diameter (approx.1:1 pa/ao ratio). No visible pericardial or free pleura fluid was noted. No echographically detectable evidence of infiltrative disease was visible. The cranial mediastinum and pericardial regions were free of masses in the visible window.

Urinary System

The urinary bladder, trigone, and pelvic urethra presented normal thicknesses and normal tone. The ureters were not visible which is normal. No uroliths or sediment were visualized, and anechoic urine was present. No evidence of inflammatory or neoplastic changes was noted. Ureteral papillae were normal.

The kidneys revealed normal size and structure, corticomedullary definition and ratio for this age. The cortices presented largely uniform texture with normal echogenic relationship to liver and spleen. Medullary structure differed distinctly from the cortex and no evidence of pelvic dilation was present. The capsules were acceptably uniform without significant irregularities.

The left kidney measured 6.5 cm.

The right kidney measured 5.4 cm.

The residual prostate measured 0.9 cm.

Adrenal Glands

Both adrenal glands were visualized and recognized as having normal shape, size, position and echogenicity for this breed. The phrenic vasculature, glandular echogenicity and detail were unremarkable. Capsule, cortex, and medullary definition were normal for this age patient.

The right adrenal gland measured 2.0 cm x 0.8 cm cranial x 0.62 caudal.

The left adrenal gland measured 2.92 cm x 0.63 cm cranial x 0.72 cm caudal.

Spleen

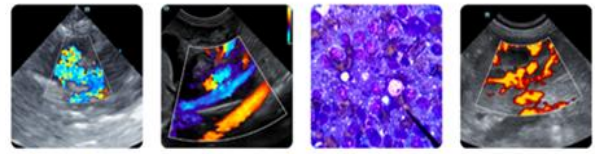
The spleen was enlarged with a mid-body irregular swelling of 5.7 cm isoechoic to the remainder of the splenic parenchyma. May be a positional abnormality given that the swelling was at the caudal fold of the spleen.

Liver

The liver images submitted revealed subtle heterogeneous parenchymal changes. The gallbladder presented acceptably thin walls with minor excessive bile noted. Minor gallbladder polyps noted with occasional parenchymal cysts measuring up to 1.1 cm x 1.5 cm. The hepatic veins were not dilated. The cystic and common bile ducts were normal. No pathological hepatic lymphadenopathy was evident.

Gastrointestinal

Examination of the gastrointestinal tract revealed a stomach and intestine free of stasis, of normal wall thickness, acceptable curvilinear mural detail, and peristaltic activity. Small and large intestine



PATIENT

demonstrated normal luminal chyme and stool consistency respectively. No obstructive or overt infiltrative disease was noted. No associated abnormal lymphatic activity was noted.

Tux Opalinski

Pancreas

SPECIES

The base and limbs of the pancreas were observed to be largely isoechoic to surrounding omental fat. Minor parenchymal remodeling, however, with mild deviation from curvilinear normalcy was observed. Pancreatic duct and capsular irregularities were present consistent with age related changes. If pain upon imaging (+ Murphy sign) was present or if the patient is focally painful in subxiphoid palpation, then low-grade smoldering chronic pancreatitis should be suspected.

Canine

BREED

Border Collie

ULTRASONOGRAPHIC FINDINGS

SEX

- Mild nodular hyperplasia vacuolar hepatopathy liver pattern

MN

- Splenic enlargement subjectively benign

AGE

13yr

- Age-related pancreas changes, minor

- Minor gallbladder polyps

- Compensated mitral insufficiency, no evidence of volume overload

INTERPRETATION OF THE FINDINGS & FURTHER RECOMMENDATIONS

WEIGHT

Largely benign abdomen with mild splenic enlargement and caudal pole swelling likely a positional abnormality, however, cannot rule out an emerging neoplastic event.

61lb

Recommend continuation of current cardiac protocol.

INTERPRETED BY

The cause of anemia is unclear, and it can justify the liver enzymes or the sonographic appearance of the liver with a benign interpretation.

Eric Lindquist, DMV
DABVP, Cert. IVUSS

If not already performed, a 25ga FNA of the mid caudal parenchymal body of the spleen would be appropriate. A CBC path review +/- bone marrow aspect may be appropriate.

IMAGING PERFORMED BY

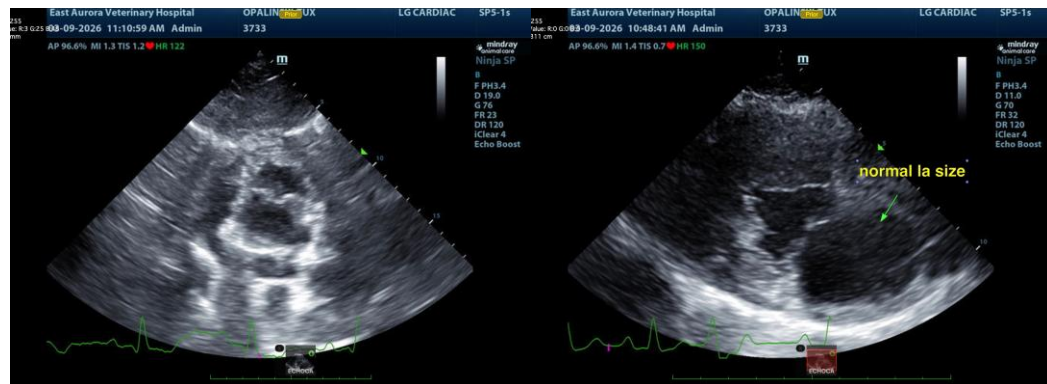
Dr Jenni Tudini, DVM

HOSPITAL NAME

Fetch the Vet Mobile
Veterinary Practice

REFERRING VET

Dr Holly Guenther

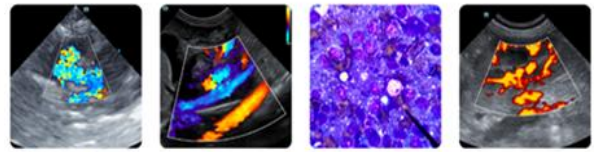


INVOICE

24174

DATE

03/11/2026



PATIENT

Tux Opalinski

SPECIES

Canine

BREED

Border Collie

SEX

MN

AGE

13yr

WEIGHT

61lb

INTERPRETED BY

Eric Lindquist, DMV
DABVP, Cert. IVUS

IMAGING PERFORMED BY

Dr Jenni Tudini, DVM

HOSPITAL NAME

Fetch the Vet Mobile
Veterinary Practice

REFERRING VET

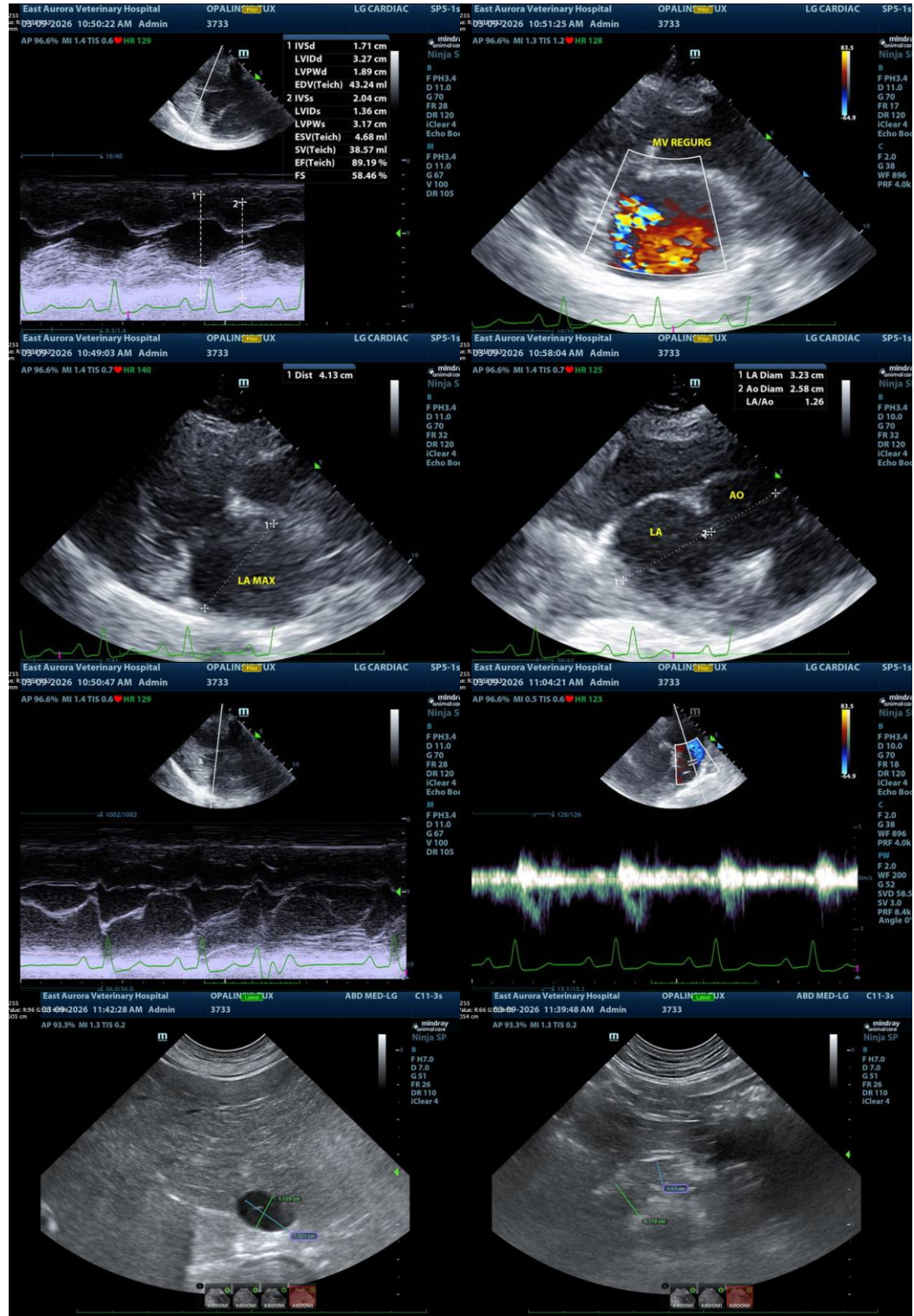
Dr Holly Guenther

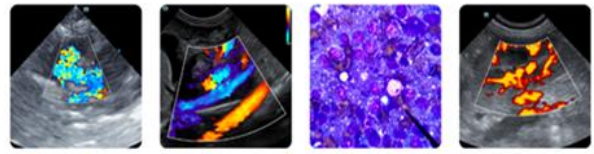
INVOICE

24174

DATE

03/11/2026





PATIENT

Tux Opalinski

The information and recommendations provided are based on the images presented by the referring veterinarian/sonographer. No evaluation can be communicated regarding pathology that was not visible in the image/video clips provided.

SPECIES

Canine

Thank you for this referral. If the clinical or image interpretation does not parallel your findings or if I can be of any further assistance, please contact me.

BREED

Border Collie

Eric Lindquist, DMV, DABVP(CFM), Cert. IVUSS,
CEO, Owner, Founder -- SonoPath.com
info@SonoPath.com

SEX

MN

AGE

13yr

WEIGHT

61lb

INTERPRETED BY

Eric Lindquist, DMV
DABVP, Cert. IVUSS

IMAGING PERFORMED BY

Dr Jenni Tudini, DVM

HOSPITAL NAME

Fetch the Vet Mobile
Veterinary Practice

REFERRING VET

Dr Holly Guenther

INVOICE

24174

DATE

03/11/2026